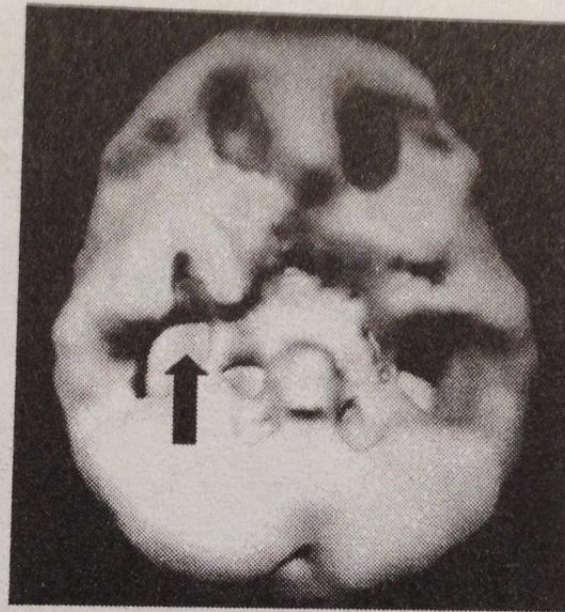


Marijuana-Affected Brains



3-D underside surface view

Sixteen-year-old male with two-year history of daily usage; notice multiple areas of markedly decreased perfusion, especially in the temporal lobes (arrow).